

REVIEW

Systematic review of structural and functional brain alterations in psychosis of epilepsy

James Allebone,¹ Richard Kanaan,^{2,3} Sarah J Wilson^{1,3,4}

¹Melbourne School of Psychological Sciences, University of Melbourne, Melbourne, Victoria, Australia

²Department of Psychiatry, University of Melbourne, Melbourne, Victoria, Australia

³Florey Institute of Neuroscience and Mental Health, Brain Research Institute (Austin Campus), Melbourne, Victoria, Australia

⁴Comprehensive Epilepsy Programme, Austin Health, Melbourne Brain Centre, Melbourne, Victoria, Australia

Correspondence to

James Allebone, Melbourne School of Psychological Sciences, University of Melbourne, Melbourne, VIC 3010, Australia; james.allebone@unimelb.edu.au

Received 17 August 2017
Revised 18 October 2017
Accepted 25 October 2017
Published Online First
23 December 2017

ABSTRACT

This systematic review critically assesses structural and functional neuroimaging studies of psychosis of epilepsy (POE). We integrate findings from 18 studies of adults with POE to examine the prevailing view that there is a specific relationship between temporal lobe epilepsy (TLE) and POE, and that mesial temporal lobe pathology is a biomarker for POE. Our results show: (1) conflicting evidence of volumetric change in the hippocampus and amygdala; (2) distributed structural pathology beyond the mesial temporal lobe; and (3) changes in frontotemporal functional network activation. These results provide strong evidence for a revised conceptualisation of POE as disorder of brain networks, and highlight that abnormalities in mesial temporal structures alone are unlikely to account for its neuropathogenesis. Understanding POE as a disease of brain networks has important implications for neuroimaging research and clinical practice. Specifically, we suggest that future neuroimaging studies of POE target structural and functional networks, and that practitioners are vigilant for psychotic symptoms in all epilepsies, not just TLE.

INTRODUCTION

Psychosis occurring in epilepsy (or psychosis of epilepsy, POE) is usually divided into postictal psychosis (PIP) and interictal psychosis (IIP). PIP occurs within 7 days of a seizure and usually involves delusions, hallucinations and/or distinct changes in affect or behaviour.¹ IIP is not obviously temporally related to seizures, and patients commonly present with paranoid delusions and hallucinations that may not resolve. Studies have consistently found a higher prevalence of psychosis in patients with epilepsy compared with the general population.^{2–8} A 2014 systematic review found an almost eightfold increased risk of psychosis in patients with epilepsy (5.6%), with a slightly higher risk in temporal lobe epilepsy (TLE; 7%).⁹ This elevated risk has intrigued researchers, as the reasons for it are unclear. Two possible mechanisms for the association have been proposed: (1) an indirect causal association between habitual seizures and damage to grey and white matter, giving rise to POE, and (2) the presence of shared risk factors giving rise to both epilepsy and psychosis.¹⁰ The majority of research to date has investigated the first mechanism, primarily using neuroimaging techniques.

In this systematic review, we provide a chronological account of the structural and functional neuroimaging literature in POE, beginning with

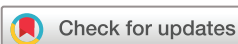early structural studies investigating the idea that abnormalities in mesial temporal lobe structures underpin its pathogenesis. Our first aim was to critically assess evidence for this ‘mesial temporal lobe hypothesis’ of POE. Epilepsy is now understood as a disease of functionally and anatomically (structurally) connected cortical and subcortical brain regions, known as ‘neural networks’.^{11–13} Because neural networks support both cognitive and behavioural functions and pathogenic processes like seizures and their comorbidities,¹⁴ the second aim of our review was to assess the neuroimaging evidence for a revised conceptualisation of POE as a network disorder.

METHOD

The methodology of our review followed PRISMA (Preferred Reporting Items for Systematic Reviews and Meta-Analyses) guidelines (figure 1). PubMed was searched systematically to identify neuroimaging studies examining brain structure and function in POE. Our search strategy was designed to maximise sensitivity while maintaining an acceptable level of specificity. We searched PubMed using the MeSH (Medical Subject Headings) search terms ‘schizophrenia spectrum and other psychotic disorders’ (MeSH Terms) AND ‘epilepsy’ (MeSH Terms) AND ‘diagnostic imaging’ (MeSH Terms). This search identified all studies containing the terms ‘schizophrenia spectrum and other psychotic disorders’ in conjunction with ‘epilepsy’ and ‘diagnostic imaging’ as well as related MeSH terms such as ‘psychosis’, ‘epilepsies’ and ‘functional neuroimaging’ in any of the fields on the PubMed database. All full-text peer-reviewed studies of humans published in English until September 2017 were included in the search. The abstracts of retrieved titles were screened by JA and studies were included if they met the following stepwise criteria: (1) described original research or meta-analyses, (2) used neuroimaging to examine changes in brain structure or function in patients with POE. All conference abstracts, unpublished studies, poster presentations and papers that were not in English, or with n<5 participants were excluded. Reference lists of selected articles were searched in order to identify any additional studies not identified through the primary search.

RESULTS

The final search identified 133 publications. Of these, 115 were excluded in a stepwise manner according to the criteria outlined in figure 1. This



To cite: Allebone J, Kanaan R, Wilson SJ. *J Neurol Neurosurg Psychiatry* 2018;**89**:611–617.

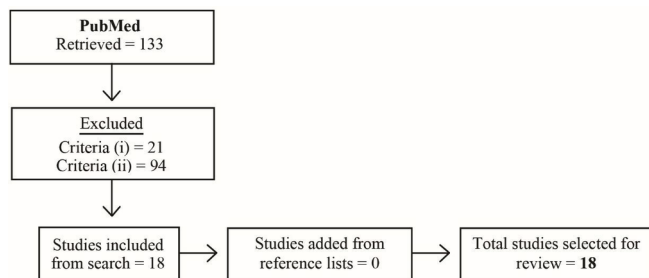


Figure 1 Flow diagram showing the search strategy for the systematic review.

resulted in 18 publications for review. Reference lists of articles identified through the search were scrutinised for additional studies that met inclusion criteria, with none identified (tables 1 and 2).

Structural neuroimaging in POE

Twelve studies using structural neuroimaging were identified. The total sample of patients with POE was n=177, comprising

IIP (n=91), PIP (n=27) and POE unspecified (n=59) groups. Five studies used manual tracing to examine the volumes of the hippocampus and amygdala. Three studies employed voxel-based morphometry (VBM) to examine differences in brain grey matter, with one study also investigating white matter, and another also examining differences in the magnetisation transfer ratio (MTR) between groups. Diffusion tensor imaging, cortical thickness, surface-based morphometry (SBM) and graph theoretical analyses were employed in four separate studies (table 1).

The mesial temporal lobe hypothesis: hippocampus and amygdala

Early structural imaging studies in POE focused on the mesial temporal lobe, following the association between TLE and psychosis first proposed in the works of Gibbs,¹⁵ Pond,¹⁶ Slater and Beard⁴ and Flor-Henry.¹⁷ A higher prevalence of POE in TLE has been identified in some,^{8 18 19} but not all,^{5 20–22} subsequent studies. Of the 18 studies identified in this systematic review, 6 specifically investigated structural neuroanatomical changes in the hippocampus and/or amygdala.^{23–28}

In 2000, Maier and colleagues compared the volume of the hippocampus/amygdala complex in patients with TLE with

Table 1 Structural neuroimaging studies in POE

Study	Year	Participants (n)	Analysis	Regions evaluated	Key results
Maier <i>et al</i> ²³	2000	12 POE, 12 EPY-NP, 26 SCZ, 38 HC	Manual tracing, spectroscopy	Hippocampus, amygdala	↓ Hippocampus/amygdala volume in POE and SCZ, but not in EPY-NP, suggesting common neuropathology
Briellmann <i>et al</i> ²⁴	2000	6 PIP, 45 EPY-NP	Manual tracing	Hippocampus	No difference in total hippocampal volumes. PIP group displayed relative anterior hippocampal preservation.
Marsh <i>et al</i> ²⁵	2001	9 IIP, 18 EPY-NP, 46 SCZ, 57 HC	Manual tracing and custom automated analysis, T2 relaxometry	Temporal lobe, superior temporal gyrus, hippocampus, ventricles, frontoparietal region	Ventricular enlargement in IIP and SCZ. Temporal and extratemporal cortical grey matter volume deficits in SCZ, IIP and EPY-NP, with greatest abnormalities in IIP group. EPY-NP group had white matter deficits in temporal lobe, and smaller hippocampi. No other differences in hippocampal volumes between groups
Tebartz van Elst <i>et al</i> ²⁶	2002	11 IIP, 15 PIP, 24 EPY-NP, 20 HC	Manual tracing, T2 relaxometry	Whole brain, hippocampus, amygdala	POE showed ↓ whole brain volume. No significant difference in hippocampal volumes between groups. Highly significant enlargement of amygdala bilaterally in POE. No significant difference in volumes between IIP and PIP
Marchetti <i>et al</i> ²⁷	2003	36 POE, 30 HC	Manual tracing	Hippocampus, amygdala	↓ Left hippocampus in POE. Hippocampal ratio significantly greater in POE (left laterality effect)
Rüsch <i>et al</i> ³⁰	2004	26 IIP and PIP, 24 EPY-NP, 20 HC	VBM (SPM99)	Whole brain	No significant differences in cortical grey matter between POE and TLE
Flügel <i>et al</i> ²⁸	2006	20 IIP, 20 EPY-NP, 23 HC	VBM (SPM2), MTR	Whole brain, hippocampus	↓ MTR signal in left superior and middle temporal gyri in patients with lesion negative IIP. No significant volumetric differences between groups in hippocampus, or other grey and white matter
Flügel <i>et al</i> ³²	2006	20 IIP, 20 EPY-NP	DTI	Middle frontal gyri, middle temporal gyri	IIP group showed ↓ fractional anisotropy in frontal and temporal regions and ↑ mean diffusivity in bilateral frontal regions. Lower fractional anisotropy related to neuropsychological performance
Sundram <i>et al</i> ³³	2010	5 PIP, 5 IIP, 10 EPY-NP	VBM (SPM5)	Whole brain	↓ Grey and white matter bilaterally in POE group as compared with EPY-NP group
DuBois <i>et al</i> ³⁴	2011	11 PIP, 11 EPY-NP, 11 HC	Cortical thickness (Freesurfer)	Cortex	↑ Cortical thickness in right lateral prefrontal cortex, rostral anterior cingulate cortex and right middle temporal gyrus in PIP compared with EPY-NP. Thinning in right angular gyrus, and left anterior inferior temporal gyrus in PIP group in comparison to EPY-NP and HC groups
Gutierrez-Galve <i>et al</i> ³⁶	2012	22 IIP, 23 EPY-NP, 20 HC	Surface-based morphometry (Freesurfer)	Cortex	↓ Cortical thickness in inferior frontal gyrus in patients with IIP. IIP group IQ associated with ↓ area (but not thickness) in frontotemporal cortex
Sone <i>et al</i> ³⁷	2016	11 POE, 15 EPY-NP, 14 HC	Graph theoretical analysis	Whole brain	↑ Path length, transitivity, ↓ global efficiency in POE relative to EPY-NP group. ↓ connectivity in contralateral temporal lobe, ipsilateral middle frontal gyrus and bilateral postcentral gyri in POE group

DTI, diffusion tensor imaging; EPY-NP, epilepsy without psychosis; HC, healthy control; IIP, interictal psychosis; MTR, magnetisation transfer ratio; PIP, postictal psychosis; POE, psychosis of epilepsy; SCZ, schizophrenia; SPM, statistical parametric mapping; TLE, temporal lobe epilepsy; VBM, voxel-based morphometry.

Table 2 Functional imaging (SPECT) studies in POE

Study	Year	Participants (n)	Timing	Key results
Mellers <i>et al</i> ³⁸	1998	12 IIP, 16 EPY-NP, 11 SCZ	Interictal SPECT	IIP group displayed hypoperfusion in left superior temporal gyrus during verbal fluency compared with word repetition relative to EPY-NP and SCZ groups.
Fong <i>et al</i> ⁴⁰	2002	6 PIP	Psychosis SPECT	Lateral temporal hyperperfusion during PIP
Leutmezer <i>et al</i> ⁴¹	2003	5 PIP	Psychosis SPECT	Bifrontal and bitemporal hyperperfusion during PIP
Guarnieri <i>et al</i> ³⁹	2005	21 IIP or PIP, 23 TLE-NP	Interictal SPECT	No significant differences. Trend for rCBF increase in right posterior cingulate in the POE group
Nishida <i>et al</i> ⁴²	2006	17 PIP, 5 postictal mania	Psychosis SPECT	Hyperperfusion in the temporal and/or frontal lobes during PIP; three patients with PIP showed increased perfusion in areas ipsilateral to the predicted epileptogenic zone.
Oshima <i>et al</i> ⁴³	2011	5 PIP	Psychosis SPECT	Three patients showed relative hyperperfusion in right temporal lobe during PIP.

EPY-NP, epilepsy without psychosis; IIP, interictal psychosis; PIP, postictal psychosis; POE, psychosis of epilepsy; rCBF, regional cerebral blood flow; SCZ, schizophrenia; SPECT, single photon emission computed tomography; TLE-NP, temporal lobe epilepsy without psychosis.

psychosis (TLE+P), patients with TLE without psychosis (TLE-NP), patients with schizophrenia, and healthy controls (HC). They found no significant differences in total hippocampal volume between any of the patient groups compared with HC. However, significant volume reductions were identified anterior to the fornix in the POE group compared with HC that were not evident in the TLE-NP group.²³ In the same year, however, Briellmann and colleagues compared patients with TLE with PIP with patients with TLE-NP and found no significant differences in hippocampal volume, and relatively *preserved* anterior hippocampal volumes in patients with PIP.²⁴

In response to these conflicting findings, and emerging evidence of brain abnormalities extending beyond the mesial temporal lobe in schizophrenia, Marsh and colleagues examined volumetric differences in the hippocampus, as well as the whole temporal lobe, superior temporal gyrus, temporal horn, lateral and third ventricles and a wedge-shaped frontoparietal region defined on the coronal image which was used as an extratemporal cortical measure.²⁵ They compared grey matter volumes in these regions in patients with different types of epilepsy and POE, TLE-NP, patients with schizophrenia and HC. Relative to HC, all patient groups displayed ventricular enlargement, and grey matter volume reductions in the temporal lobe, frontoparietal regions and superior temporal gyrus, with the POE group demonstrating the greatest reductions. The POE group did not display differences in hippocampal volume, and only the TLE-NP group had reduced hippocampal volumes. These findings were the first to suggest that pathology beyond the mesial temporal region may be implicated in the pathogenesis of POE.

In 2002, Tebartz van Elst and colleagues conducted a volumetric study of the hippocampus and amygdala comparing patients with TLE+P, patients with TLE-NP, and HC.²⁶ This was the first study to separately measure the hippocampus and amygdala, and specifically examine the role of the amygdala in POE. No significant differences in hippocampal volumes were identified; however, both PIP and IIP groups displayed bilateral enlargement of the amygdala. Both POE subgroups also displayed significant cortical volume loss, in line with the developing view that POE neuropathology may not be circumscribed to the mesial temporal lobe. The authors pointed out that in contrast to their findings, studies of structural alterations in schizophrenia have consistently found grey matter volume loss in the amygdala,²⁹ suggesting that POE develops via a different neuropathological mechanism.

In 2003, Marchetti and colleagues identified reduced left hippocampal volumes in POE as compared with HC. However, given the lack of an epilepsy comparison group, the specificity of these findings to POE, as opposed to epilepsy in general, is

unclear.²⁷ Finally, no differences in hippocampal volume were identified between patients with TLE with and without psychosis in a 2006 study by Flügel *et al*.²⁸

Extramesial temporal structural abnormalities in POE

As noted above, the first neuroimaging study to specifically examine grey matter volumes outside the mesial temporal lobe was undertaken by Marsh *et al*.²⁵ They found widespread temporal and extratemporal cortical grey matter reductions in both POE and schizophrenia, with the greatest reductions in the POE group. In their 2002 study, Tebartz van Elst *et al* also found reduced total brain volume in POE compared with TLE-NP.²⁶ Tebartz van Elst's group then conducted a second study³⁰ with the same cohort of patients with POE, focusing on cortical grey matter volume abnormalities; however, no significant differences were found.

In 2006, Flügel and colleagues carried out two studies of white matter in POE. They first used magnetisation transfer imaging (MTI) to explore differences in white matter between 20 patients with TLE with IIP, 20 patients with TLE-NP, and 23 HC. MTI derives a putative measure of white matter abnormalities called the MTR.²⁸ Both the IIP and TLE-NP groups comprised 10 patients with hippocampal sclerosis (HS) and 10 patients with no focal lesion on MRI. They found no significant MTR differences between the IIP and TLE-NP groups. However, comparison of the non-lesional IIP and TLE-NP patients revealed significantly lower MTR in the left middle and superior temporal gyri in the IIP group. In a separate study, Flügel *et al*³¹ found a significant correlation between MTR reduction in the left fusiform gyrus and verbal fluency in the IIP group only.

Flügel *et al*'s³² second study examined the same cohort of patients with IIP using diffusion weighted imaging to make inferences about white matter microstructure, directionality and coherence.³² Flügel *et al* found significant white matter abnormalities in frontotemporal regions in patients with IIP compared with epilepsy patients without psychosis (EPY-NP), which correlated with impaired performance on neuropsychological tests of visuospatial working memory.

In 2010, Sundram *et al* conducted a whole brain VBM study of 10 TLE patients with POE (5 PIP, 5 IIP) and 10 TLE-NP patients, again excluding patients with POE with an extratemporal focus, or generalised or unclassified seizures.³³ They found widespread grey matter deficits in the POE group including in lateral and extratemporal regions. Sundram *et al* also reported white matter deficits in the POE group in mesial temporal, lateral temporal, and extratemporal regions.

Two studies examined cortical thickness in POE. The first used SBM in 11 patients with PIP, 11 patients with EPY-NP and a matched HC group.³⁴ Importantly, this study included patients with extratemporal seizure foci, which are relatively common in PIP.³⁵ Compared with the EPY-NP patients, the PIP group displayed cortical thickening in the right lateral prefrontal cortex, right rostral anterior cingulate cortex (ACC) and right middle temporal gyrus. Relative to both groups, patients with PIP showed increased cortical thickness in right rostral ACC, and areas of thinning in the right angular gyrus and left anterior inferior temporal gyrus. The second study also used SBM in patients with TLE and IIP, identifying reduced cortical thickness in the inferior frontal gyrus of patients with IIP compared with HC.³⁶ This difference was not observed between patients with TLE-NP and controls. Lower IQ was significantly associated with less cortical area (but not thickness) in regions of the frontotemporal cortex in the POE group.

Finally, Sone *et al* used graph theoretical analysis to compare the structural connectivity in 11 TLE patients with HS and POE, 15 patients with TLE-NP with HS, and 14 HC.³⁷ The results identified disrupted connectivity in the contralateral hemisphere and decreased efficiency of the whole brain network in the POE group.

Functional neuroimaging in POE

Six studies of cerebral perfusion in patients with POE were identified (table 2). The total sample of patients with POE was n=66, comprising IIP (n=12), PIP (n=33) and unspecified POE (n=21) groups. All studies used single photon emission computed tomography (SPECT), which involves intravenous injection of a radioisotope or tracer that emits gamma rays detectable by a nuclear gamma camera that are thought to index neuronal activity.

SPECT during the interictal period

In 1998, Mellers *et al* examined the regional cerebral blood flow (rCBF) in 12 patients with IIP, 16 patients with EPY-NP, and 11 patients with schizophrenia. Measurements were taken interictally while patients performed a verbal fluency task, and again during a control task (word repetition). Differences in perfusion were examined in frontal and temporal cortical regions. When comparing group level activation during the tasks, the schizophrenia group showed hyperactivation in the ACC, while the IIP group showed hypoactivation in the left superior temporal cortex.³⁸ In 2005, a second interictal SPECT study was conducted with 21 POE patients with mesial TLE and HS.³⁹ The POE group included both patients with IIP and PIP, and their interictal SPECT activation was compared with 23 matched EPY-NP patients. No statistically significant differences in perfusion were identified in any of the regions of interest evaluated (frontal, temporal and parietal cortex, and subcortical regions).

SPECT during PIP

In contrast to interictal SPECT studies, a series of SPECT studies during PIP have consistently found hyperperfusion. Fong *et al*⁴⁰ compared baseline rCBF with rCBF during PIP in six patients with either partial or generalised seizures, finding focal hyperperfusion over the lateral temporal cortex during PIP. In a similar study with five TLE patients with PIP, Leutmezer *et al*⁴¹ found that all patients displayed bifrontal and bitemporal hyperperfusion during psychosis in comparison to the non-psychotic state. Nishida and colleagues⁴² examined changes in functional activation in 17 patients with PIP and 5 patients with postictal mania during periods of PIP and mania, respectively. Results

Box 1 Key findings of review and methodological limitations of past studies

Key findings

- ▶ Inconsistent results across structural neuroimaging studies.
- ▶ Emerging evidence of structural changes in extramesial temporal regions.
- ▶ Frontotemporal hyperperfusion during PIP.
- ▶ Strong evidence for POE as a disease of brain networks.

Methodological limitations and sources of bias

- ▶ Exclusion of non-TLE subjects in most studies.
- ▶ Lack of comparison groups and small sample sizes in some studies.
- ▶ Manual tracing studies have excluded posterior hippocampal regions, included non-hippocampal tissue and used varying tracing protocols.
- ▶ Focus on mesial-temporal structures to the exclusion of wider cortical regions due to early reports of higher rates of POE in TLE, and mesial temporal pathology in schizophrenia.
- ▶ Some studies report results at the individual rather than group level.
- ▶ Visual inspection of SPECT images as method of analysis.

PIP, postictal psychosis; POE psychosis of epilepsy; SPECT, single photon emission computed tomography; TLE, temporal lobe epilepsy.

were reported at the individual patient level, limiting the power of findings, and analysis was by visual inspection only, which limits confidence in the results. Nonetheless, increased perfusion during PIP was noted in the language-dominant temporal lobe in one patient, the non-language-dominant temporal lobe and frontal lobe in a second patient, and in the non-language-dominant hemisphere in a third patient with PIP compared with during a lucid interval. Finally, Oshima and colleagues⁴³ conducted a SPECT study in five patients with PIP. They found right temporal hyperperfusion in three of the five patients. In the remaining two patients, one showed right temporal hypoperfusion interictally, and bitemporal hypoperfusion during PIP, while the other showed left hemisphere hypoperfusion interictally and left temporal hypoperfusion during PIP, suggesting that hypoperfusion was not related to PIP in these cases. As in the study by Nishida *et al*,⁴² analysis in this study was limited to visual inspection of SPECT images.

DISCUSSION

To our knowledge, this is the first systematic review of the structural and functional neuroimaging literature in POE. The key results of the review include: (1) inconsistent findings across the POE structural neuroimaging literature, particularly research examining hippocampal volumes; (2) emerging evidence of structural changes in extramesial temporal regions and whole-brain structural networks; and (3) frontotemporal hyperperfusion during PIP in SPECT functional imaging studies. Combined, these results support a reconceptualisation of POE as a disease of brain networks. Key findings of this review and methodological limitations of past studies are summarised in box 1.

Findings and limitations of manual volumetry studies in POE

One interpretation of the inconsistency across studies of hippocampal volumes in POE is that the hippocampus is not primarily implicated in its pathogenesis. However, the protocols used to define the anatomical boundaries of the hippocampus

Table 3 Characteristics of manual tracing studies of hippocampal volumes in POE

Study	Raters (n)	Intrarater reliability coefficient	Inter-rater reliability coefficient	Anatomical definition
Marchetti <i>et al</i> ²⁷	2	0.93–0.99	0.74–0.95	As per Watson <i>et al</i> ⁴⁹
Tebartz van Elst <i>et al</i> ²⁶	1	0.99 (hippocampus), 0.88 (amygdala)	–	As per Watson <i>et al</i> ⁴⁹
Marsh <i>et al</i> ²⁵	–	–	0.90, right hippocampus=0.84	Anterior=amygdala. Posterior=oneslice anterior to: (1) ascending hippocampal tail (ie, tail not included), (2) absence of vertical fissures for lateral sulcus, (3) appearance of ventricular trigone
Briellmann <i>et al</i> ²⁴	–	–	–	–
Maier <i>et al</i> ²³	1	–	–	As per Cook <i>et al</i> ⁴⁶ and Hasboun <i>et al</i> ⁵⁰ Tail not included. No separation of hippocampus and amygdala

–, not reported; POE, psychosis of epilepsy.

in all studies of POE exclude the hippocampal tail (table 3), which comprises a significant proportion of the hippocampus (figure 2). The volume of the hippocampal tail has been shown to be reduced in other psychiatric disorders, including schizophrenia⁴⁴ and depression⁴⁵ with reductions greatest in the tail, highlighting the potential importance of this region in POE. Further, some study protocols explicitly included non-hippocampal tissue (choroid plexus)⁴⁶ while others treated the hippocampus and amygdala as a single structure.²³ Given the distinct roles and structural and functional connectivity of the hippocampus and amygdala, it would be prudent to measure these structures separately in future volumetric studies using a reliable protocol that divides the hippocampus into its component subregions, including the hippocampal tail. A harmonised protocol for hippocampal segmentation on magnetic resonance (HarP) has recently been developed as the gold standard method for hippocampal volumetry in Alzheimer's disease.⁴⁷ This protocol captures 100% of hippocampal tissue including the tail,⁴⁸ and has high measurement stability. An example of manual hippocampal

volumetry using the HarP protocol, which shows the extent of the hippocampus including the tail (traced by JA), is presented in figure 2.

Other limitations of some of the manual tracing studies of the hippocampus in POE include the lack of an epilepsy comparison group²⁷ and small sample sizes (all studies <40 subjects (table 3)).^{46 49 50} Despite these shortcomings, the lack of consistent evidence of changes in mesial temporal regions in POE suggests that its aetiology involves extramesial temporal regions, although this does not exclude the possibility of hippocampal involvement.

Beyond the mesial temporal hypothesis: distributed structural networks and POE

Our review of structural neuroimaging studies in POE suggests that as in schizophrenia, the neuropathology underpinning POE involves distributed brain regions and cannot be localised specifically to the mesial temporal lobe. As such, we suggest that network dysfunction, rather than a localised lesion, underpins POE. In support of this, epilepsy is increasingly understood as a network disease, with histological and architectural changes identified in neocortical⁵¹ and thalamic regions^{52 53} in TLE, and MRI studies identifying atrophy in regions distal to the seizure focus.^{54 55} White matter abnormalities in tracts extending beyond the seizure focus have been identified in both children⁵⁶ and adults with TLE, with associated cognitive deficits.^{57 58} Similarly, in schizophrenia, grey matter changes are widespread, with a clear relationship to disease progression.⁵⁹ For example, significantly higher loss of total cortical grey matter volume has been identified in patients with schizophrenia compared with HC.^{29 60} A systematic meta-review of structural brain alterations in schizophrenia found evidence for widely distributed grey matter reductions involving the ACC, frontal and temporal lobes, mesial temporal structures and insula.⁶¹ The evidence for widespread changes in brain structure in both epilepsy and schizophrenia, and emerging evidence of reduced structural network efficiency in POE,³⁷ strongly support the overall findings of the present review, and the reconceptualisation of POE as a disease of brain networks.

Frontotemporal hyperperfusion in POE

If the results of SPECT studies in POE are considered overall, 17/19 (89%) of the patients assessed during PIP showed hyperperfusion, with 12/19 (63%) showing hyperperfusion in the right temporal lobe, 10/19 (53%) in the left temporal lobe and 7/19 (37%) in the frontal lobes. When the two patients from the study by Oshima and colleagues who showed hypoperfusion both interictally and during PIP are excluded (suggesting

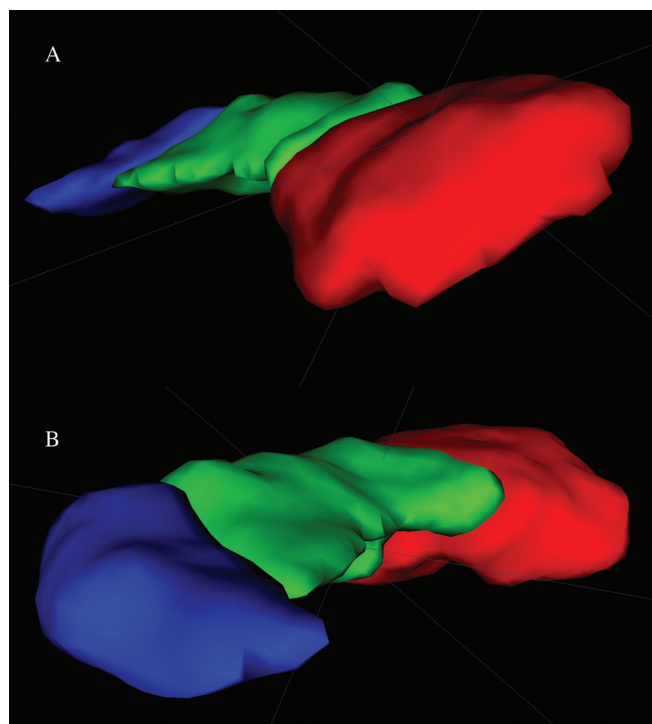


Figure 2 Three-dimensional render of the hippocampus traced according to the HarP protocol. (A) Anterior view. (B) Posterior view. Red=hippocampal head, green=hippocampal body, blue=hippocampal tail.

that hypoperfusion was not related to PIP), 100% of patients showed hyperperfusion during PIP. Therefore, we suggest that in clinical practice, patients who show hyperperfusion in frontotemporal networks on interictal SPECT are monitored for symptoms of psychosis, as they may be experiencing a subtle postictal psychotic episode.

It has been suggested that hyperperfusion may reflect ongoing epileptogenic discharges not detectable on scalp electroencephalography (EEG) during PIP. This view is supported by studies that showed abnormal subcortical EEG patterns which appeared during PIP and ceased at its termination in patients implanted with depth electrodes.⁶² Nonetheless, other studies using depth electrodes have not identified abnormal EEG activity during PIP, suggesting that PIP is not underpinned by ongoing focal epileptic discharges, but rather may involve more widespread neural network dysfunction.⁶³ One explanation for the relative consistency of these findings compared with structural neuroimaging studies which focus on a region of interest is that SPECT studies do not focus on a particular region of interest (eg, the hippocampus) a priori. Nonetheless, given the different methodologies used across studies—including analysis by visual inspection—and relatively small sample sizes, these findings need to be interpreted with caution. Moreover, due to the lack of research separately examining patients with IIP, no clear distinction in functional activation can currently be made between the two main POE subtypes. We therefore suggest that further functional imaging research in POE is warranted. An obvious first step would be a resting-state study using functional MRI as this is a more sophisticated technique with significantly greater spatial resolution than SPECT.

POE as a potential comorbidity of epilepsy, not just TLE

A notable finding of our review is that most studies excluded non-TLE patients. This is likely due to the historical view that TLE carries a significantly higher risk for POE than the other epilepsies, and early research highlighting mesial temporal pathology in schizophrenia. We now know that there is only a slight increase in risk of POE in TLE relative to other epilepsies⁹ and that structural brain alterations in schizophrenia occur outside the mesial temporal region.⁶¹ In light of the findings of our review, we suggest that future research includes all patients with POE, regardless of epilepsy type. In support of this argument, we have shown that studies of hippocampal volumes in POE have produced inconsistent results, that recent structural imaging studies which include regions beyond the mesial temporal lobe have identified widespread extratemporal pathology in both grey^{25 33 34} and white matter^{28 32 33} in POE, and that POE is characterised by frontotemporal hyperperfusion.^{40–43}

CONCLUSIONS

This systematic review provides a critical appraisal of the structural and functional neuroimaging literature in POE, finding minimal support for the 'mesial temporal lobe hypothesis'. Perhaps due to methodological limitations and small sample sizes, studies employing manual volumetry of the hippocampus have produced inconsistent findings, while structural neuroimaging studies examining the whole brain suggest distributed neuropathology in POE. The functional imaging literature consistently highlights hyperperfusion in frontotemporal networks. Combined, these findings point to a reconceptualisation of POE as a disease of brain networks and suggest that at the neuro-anatomical level, POE is underpinned by distributed structural pathology in grey and white matter, and hyperperfusion within

frontotemporal networks. Understanding POE as a disease of brain networks has important implications for future neuroimaging research and clinical practice. Specifically, we suggest that future studies target structural and functional networks rather than localised structural pathology, and that frontotemporal networks become a particular focus of this work. Moreover, patients who show frontotemporal hyperperfusion on interictal SPECT should be closely monitored in order to rule out a subtle episode of PIP. Importantly, by showing that neuropathology in POE extends beyond the mesial temporal lobe, our review also supports recent prevalence studies which highlight that POE is comorbid in many epilepsies. For clinical practice, this implies that those caring for people with epilepsy should remain vigilant for psychotic symptoms in all epilepsies, as POE does not currently appear to be particular to a specific electroclinical syndrome.

Acknowledgements We thank our colleagues in Melbourne School of Psychological Sciences at the University of Melbourne, the Florey Institute of Neuroscience and Mental Health, and the Comprehensive Epilepsy Programme at Austin Health for their ongoing support.

Contributors JA: study concept and design, acquisition of data, analysis and interpretation of data, drafting and critical revision of the manuscript for intellectual content. RK and SJW: study concept and design, critical revision of the manuscript for intellectual content.

Competing interests None declared.

Provenance and peer review Not commissioned; externally peer reviewed.

© Article author(s) (or their employer(s) unless otherwise stated in the text of the article) 2018. All rights reserved. No commercial use is permitted unless otherwise expressly granted.

REFERENCES

- Logsdail SJ, Toone BK. Post-ictal psychoses. A clinical and phenomenological description. *Br J Psychiatry* 1988;152:246–52.
- Gudmundsson G. Epilepsy in Iceland. A clinical and epidemiological investigation. *Acta Neurol Scand* 1966;43:1–124.
- Gibbs EL, Gibbs FA, Fuster B. Psychomotor epilepsy. *Arch Neurol Psychiatry* 1948;60:331–9.
- Slater E, Beard AW. The schizophrenia-like psychoses of epilepsy: i. psychiatric aspects. *Br J Psychiatry* 1963;109:95–112.
- Schmitz B, Wolf P. Psychosis in epilepsy: frequency and risk factors. *J Epilepsy* 1995;8:295–305.
- Jensen I, Larsen JK. Mental aspects of temporal lobe epilepsy. Follow-up of 74 patients after resection of a temporal lobe. *J Neurol Neurosurg Psychiatry* 1979;42:256–65.
- McKenna PJ, Kane JM, Parrish K. Psychotic syndromes in epilepsy. *Am J Psychiatry* 1985;142:895–904.
- Gaitatzis A, Trimble MR, Sander JW. The psychiatric comorbidity of epilepsy. *Acta Neurol Scand* 2004;110:207–20.
- Clancy MJ, Clarke MC, Connor DJ, et al. The prevalence of psychosis in epilepsy; a systematic review and meta-analysis. *BMC Psychiatry* 2014;14:75.
- Adachi N, Onuma T, Kato M, et al. Analogy between psychosis antedating epilepsy and epilepsy antedating psychosis. *Epilepsia* 2011;52:1239–44.
- Spencer SS. Neural networks in human epilepsy: evidence of and implications for treatment. *Epilepsia* 2002;43:219–27.
- van Diessen E, Diederer SJ, Braun KP, et al. Functional and structural brain networks in epilepsy: what have we learned? *Epilepsia* 2013;54:1855–65.
- Engel J, Thompson PM, Stern JM, et al. Connectomics and epilepsy. *Curr Opin Neurol* 2013;26:186–94.
- Wilson SJ, Baxendale S. The new approach to classification: rethinking cognition and behavior in epilepsy. *Epilepsy Behav* 2014;41:307–10.
- Gibbs FA. Ictal and non-ictal psychiatric disorders in temporal lobe epilepsy. *J Nerv Ment Dis* 1951;113:522–8.
- Pond D. Psychiatric aspects of epilepsy. *J Indian Med Prof* 1957;3:1421–51.
- Flor-Henry P. Psychosis and temporal lobe epilepsy. A controlled investigation. *Epilepsia* 1969;10:363–95.
- Shukla GD, Srivastava ON, Katiyar BC, et al. Psychiatric manifestations in temporal lobe epilepsy: a controlled study. *Br J Psychiatry* 1979;135:411–7.
- Hilger E, Zimprich F, Patarraia E, et al. Psychoses in epilepsy: a comparison of postictal and interictal psychoses. *Epilepsy Behav* 2016;60:58–62.

- 20 Adams SJ, O'Brien TJ, Lloyd J, *et al.* Neuropsychiatric morbidity in focal epilepsy. *Br J Psychiatry* 2008;192:464–9.
- 21 Adachi N, Onuma T, Hara T, *et al.* Frequency and age-related variables in interictal psychoses in localization-related epilepsies. *Epilepsy Res* 2002;48:25–31.
- 22 Schmitz EB, Robertson MM, Trimble MR. Depression and schizophrenia in epilepsy: social and biological risk factors. *Epilepsy Res* 1999;35:59–68.
- 23 Maier M, Mellers J, Toone B, *et al.* Schizophrenia, temporal lobe epilepsy and psychosis: an in vivo magnetic resonance spectroscopy and imaging study of the hippocampus/amygdala complex. *Psychol Med* 2000;30:571–81.
- 24 Briellmann RS, Kalnins RM, Hopwood MJ, *et al.* TLE patients with postictal psychosis: mesial dysplasia and anterior hippocampal preservation. *Neurology* 2000;55:1027–30.
- 25 Marsh L, Sullivan EV, Morrell M, *et al.* Structural brain abnormalities in patients with schizophrenia, epilepsy, and epilepsy with chronic interictal psychosis. *Psychiatry Res* 2001;108:1–15.
- 26 Tebartz van Elst L, Baeumer D, Lemieux L, *et al.* Amygdala pathology in psychosis of epilepsy: A magnetic resonance imaging study in patients with temporal lobe epilepsy. *Brain* 2002;125:140–9.
- 27 Marchetti RL, Azevedo D, de Campos Bottino CM, *et al.* Volumetric evidence of a left laterality effect in epileptic psychosis. *Epilepsy Behav* 2003;4:234–40.
- 28 Flügel D, Cercignani M, Symms MR, *et al.* A magnetization transfer imaging study in patients with temporal lobe epilepsy and interictal psychosis. *Biol Psychiatry* 2006;59:560–7.
- 29 Bora E, Fornito A, Radua J, *et al.* Neuroanatomical abnormalities in schizophrenia: a multimodal voxelwise meta-analysis and meta-regression analysis. *Schizophr Res* 2011;127:46–57.
- 30 Rüsçh N, Tebartz van Elst L, Baeumer D, *et al.* Absence of cortical gray matter abnormalities in psychosis of epilepsy: a voxel-based MRI study in patients with temporal lobe epilepsy. *J Neuropsychiatry Clin Neurosci* 2004;16:148–55.
- 31 Flügel D, O'Toole A, Thompson PJ, *et al.* A neuropsychological study of patients with temporal lobe epilepsy and chronic interictal psychosis. *Epilepsy Res* 2006;71:117–28.
- 32 Flügel D, Cercignani M, Symms MR, *et al.* Diffusion tensor imaging findings and their correlation with neuropsychological deficits in patients with temporal lobe epilepsy and interictal psychosis. *Epilepsia* 2006;47:941–4.
- 33 Sundram F, Cannon M, Doherty CP, *et al.* Neuroanatomical correlates of psychosis in temporal lobe epilepsy: voxel-based morphometry study. *Br J Psychiatry* 2010;197:482–92.
- 34 DuBois JM, Devinsky O, Carlson C, *et al.* Abnormalities of cortical thickness in postictal psychosis. *Epilepsy Behav* 2011;21:132–6.
- 35 Alper K, Kuzniecky R, Carlson C, *et al.* Postictal psychosis in partial epilepsy: a case-control study. *Ann Neurol* 2008;63:602–10.
- 36 Gutierrez-Galve L, Flügel D, Thompson PJ, *et al.* Cortical abnormalities and their cognitive correlates in patients with temporal lobe epilepsy and interictal psychosis. *Epilepsia* 2012;53:1077–87.
- 37 Sone D, Matsuda H, Ota M, *et al.* Graph theoretical analysis of structural neuroimaging in temporal lobe epilepsy with and without psychosis. *PLoS One* 2016;11:e0158728.
- 38 Mellers JD, Adachi N, Takei N, *et al.* SPET study of verbal fluency in schizophrenia and epilepsy. *Br J Psychiatry* 1998;173:69–74.
- 39 Guarneri R, Wichert-Ana L, Hallak JE, *et al.* Ictal SPECT in patients with mesial temporal lobe epilepsy and psychosis: a case-control study. *Psychiatry Res* 2005;138:75–84.
- 40 Fong GC, Ho WY, Tsoi TH, *et al.* Lateral temporal hyperperfusion in postictal psychosis assessed by 99mTc-HMPAO SPECT. *Neuroimage* 2002;17:1634–7.
- 41 Leutmezer F, Podreka I, Asenbaum S, *et al.* Postictal psychosis in temporal lobe epilepsy. *Epilepsia* 2003;44:582–90.
- 42 Nishida T, Kudo T, Inoue Y, *et al.* Postictal mania versus postictal psychosis: differences in clinical features, epileptogenic zone, and brain functional changes during postictal period. *Epilepsia* 2006;47:2104–14.
- 43 Oshima T, Motooka H, Kanemoto K. SPECT findings during postictal psychoses: predominance of relative increase of perfusion in right temporal lobe. *Epilepsia* 2011;52:1192–4.
- 44 Maller JJ, Daskalakis ZI, Thomson RH, *et al.* Hippocampal volumetrics in treatment-resistant depression and schizophrenia: the devil's in de-tail. *Hippocampus* 2012;22:9–16.
- 45 Maller JJ, Daskalakis ZI, Fitzgerald PB. Hippocampal volumetrics in depression: the importance of the posterior tail. *Hippocampus* 2007;17:1023–7.
- 46 Cook MJ, Fish DR, Shorvon SD, *et al.* Hippocampal volumetric and morphometric studies in frontal and temporal lobe epilepsy. *Brain* 1992;115(Pt 4):1001–15.
- 47 Frisoni GB, Jack CR, Bocchetta M, *et al.* The EADC-ADNI harmonized protocol for manual hippocampal segmentation on magnetic resonance: evidence of validity. *Alzheimers Dement* 2015;11:111–25.
- 48 Boccardi M, Bocchetta M, Apostolova LG, *et al.* Delphi definition of the EADC-ADNI Harmonized Protocol for hippocampal segmentation on magnetic resonance. *Alzheimers Dement* 2015;11:126–38.
- 49 Watson C, Andermann F, Gloor P, *et al.* Anatomic basis of amygdaloid and hippocampal volume measurement by magnetic resonance imaging. *Neurology* 1992;42:1743–50.
- 50 Hasboun D, Chantôme M, Zouaoui A, *et al.* MR determination of hippocampal volume: comparison of three methods. *AJNR Am J Neuroradiol* 1996;17:1091–8.
- 51 Blanc F, Martinian L, Liagkouras I, *et al.* Investigation of widespread neocortical pathology associated with hippocampal sclerosis in epilepsy: a postmortem study. *Epilepsia* 2011;52:10–21.
- 52 Bernhardt BC, Bonilha L, Gross DW. Network analysis for a network disorder: The emerging role of graph theory in the study of epilepsy. *Epilepsy Behav* 2015;50:162–70.
- 53 Bernasconi N, Bernasconi A, Caramanos Z, *et al.* Mesial temporal damage in temporal lobe epilepsy: a volumetric MRI study of the hippocampus, amygdala and parahippocampal region. *Brain* 2003;126:462–9.
- 54 Bernhardt BC, Bernasconi N, Kim H, *et al.* Mapping thalamocortical network pathology in temporal lobe epilepsy. *Neurology* 2012;78:129–36.
- 55 Lin JJ, Salamon N, Lee AD, *et al.* Reduced neocortical thickness and complexity mapped in mesial temporal lobe epilepsy with hippocampal sclerosis. *Cereb Cortex* 2007;17:2007–18.
- 56 Meng L, Xiang J, Kotecha R, *et al.* White matter abnormalities in children and adolescents with temporal lobe epilepsy. *Magn Reson Imaging* 2010;28:1290–8.
- 57 Riley JD, Franklin DL, Choi V, *et al.* Altered white matter integrity in temporal lobe epilepsy: association with cognitive and clinical profiles. *Epilepsia* 2010;51:536–45.
- 58 Yogarajah M, Powell HW, Parker GJ, *et al.* Tractography of the parahippocampal gyrus and material specific memory impairment in unilateral temporal lobe epilepsy. *Neuroimage* 2008;40:1755–64.
- 59 Velakoulis D, Wood SJ, Wong MTH, *et al.* Hippocampal and amygdala volumes according to psychosis stage and diagnosis. *Arch Gen Psychiatry* 2006;63:139–49.
- 60 Vita A, De Peri L, Deste G, *et al.* Progressive loss of cortical gray matter in schizophrenia: a meta-analysis and meta-regression of longitudinal MRI studies. *Trans Psychiatry* 2012;2:e190–13.
- 61 Shepherd AM, Laurens KR, Matheson SL, *et al.* Systematic meta-review and quality assessment of the structural brain alterations in schizophrenia. *Neurosci Biobehav Rev* 2012;36:1342–56.
- 62 Kuba R, Brázdil M, Rektor I. Postictal psychosis and its electrophysiological correlates in invasive EEG: a case report study and literature review. *Epilepsy Behav* 2012;23:426–30.
- 63 Schulze-Bonhage A, van Elst LT. Postictal psychosis: Evidence for extrafocal functional precursors. *Epilepsy Behav* 2010;18:308–12.